



This page is left blank

This page is left blank



Defence Research and  
Development Canada    Recherche et développement  
pour la défense Canada



# **Part I: Development of an animal model to investigate the 2D and 3D high image resolution ultrasonic technology using synthetic aperture and adaptive beamformers**

*Z.E. Suntres  
S. Stergiopoulos*

**Defence R&D Canada – Toronto**  
Technical Report  
DRDC Toronto TR 2002-023  
April 2002

**Canada**

# **Part I: Development of an animal model to investigate the 2D and 3D high image resolution ultrasonic technology using synthetic aperture and adaptive beamformers**

Z. E. Suntres  
S. Stergiopoulos



**Defence R&D Canada - Toronto**

Technical Report

DRDC Toronto TR 2002-023

April 2002


Author

---

Z.E. Suntres and S. Stergiopoulos

Approved by



---

Dr. P.N. Shek

Head / Operational Medicine Section

Approved for release by



---

K.M. Sutton

Chair / Document Review and Library Committee

## Abstract

In recent years, it has been demonstrated that the current ultrasound imaging system may be unreliable due to its poor imaging quality; in several instances, it lacks clarity, specificity, resolution, and sensitivity. These disadvantages have negative consequences when diagnosing patients since false-positive or false-negative results are sometimes inescapable. It is therefore of great importance to design a new ultrasound imaging system that is able to enhance the images provided by the current technology and subsequently prevent chances for misdiagnosis.

An animal model of organ injuries has been established where the current technology in ultrasonography will be tested and compared to the newly developed 3-D ultrasound technology. For this, the effect of lipopolysaccharide (LPS), a bacterial cell wall component, on the lung, liver, and kidney organs of rabbits was examined. Administration of LPS to animals was more or less injurious to all organs examined as evidenced by an increase in organ weights. In addition, a significant increase in lipid peroxidation as well as reduction in glutathione levels in tissue homogenates, confirmed the involvement of oxidative stress as a major mechanism of LPS-induced tissue injury.

## Résumé

Il a été démontré au cours des dernières années que le système actuel d'imagerie par ultrasons pourrait ne pas être fiable en raison de ses piètres qualités sur le plan de la formation de l'image; bien souvent, la clarté, la spécificité, la résolution et la sensibilité de ce système sont insatisfaisantes. Ces inconvénients ont des répercussions fâcheuses sur le diagnostic des patients, car les résultats faux négatifs ou faux positifs sont parfois inévitables. Il est par conséquent très important de concevoir un nouveau système d'imagerie par ultrasons permettant d'améliorer la qualité des images produites par la technologie actuelle et, par la suite, de prévenir les risques d'erreur de diagnostic.

Un modèle animal de lésions d'organes a été élaboré afin de mettre à l'essai et de comparer la technologie actuelle d'ultrasonographie et la technologie récemment mise au point d'imagerie par ultrasons 3D. Pour ce faire, on a examiné l'effet des lipopolysaccharides (LPS), un constituant de la paroi cellulaire bactérienne, sur les poumons, le foie et les reins chez le lapin. L'administration de LPS aux animaux a provoqué des lésions plus ou moins graves de tous les organes examinés, comme l'atteste l'augmentation du poids des organes observée. En outre, une augmentation significative de la peroxydation des lipides et une diminution des taux de glutathione dans les homogénats tissulaires ont confirmé que le stress oxydatif joue un rôle de premier plan dans la lésion des tissus provoquée par les LPS.

This page intentionally left blank.

## Executive summary

During various military operations, injuries to the abdominal region are extremely common. Damage to organs such as the lung, liver, spleen, and kidney may be fatal if misdiagnosed. Furthermore, conditions such as gastrointestinal trauma, and internal bleeding or hemorrhaging are often overlooked since there are no field-deployable imaging techniques available to diagnose such conditions. Currently, conventional ultrasound images are 2D and the operator must mentally integrate multiple images to develop a 3D impression of the anatomy/pathology during a procedure, a practice that is time-consuming, inefficient, and requires a highly skilled operator, all of which can potentially lead to incorrect diagnostic and therapeutic decisions. Thus, there is a great need to develop a field-deployable imaging system that can increase the probability of correct diagnosis in order to ensure appropriate treatment.

Our fundamental purpose, is to develop a next-generation field-portable 3-D ultrasound diagnostic imaging system. This system will deploy planar arrays with the implementation of adaptive and synthetic aperture processing for high image resolution. This system will include: 1) adaptive and synthetic aperture beamforming schemes to provide high image-resolution for ultrasound diagnostic systems that will be equivalent with those deploying 9-time larger planar arrays; and, 1) 3D visualization imaging techniques to assist real time imaging during minimally invasive operations.

To validate the superiority of the 3D High Image Resolution Ultrasound technology over the existing 2-D ultrasound technology, it is necessary to perform experiments on animal models. Most of the animal work conducted with ultrasound has been performed on rabbits. Therefore, it is proposed to obtain images of normal and of injured organs in rabbits using the current technology in ultrasonography and compare these results to the newly developed 3-D ultrasound technology.

To establish an animal model of organ injuries, the effect of lipopolysaccharide (a bacterial cell wall component commonly used to induce the pathological conditions observed in sepsis and trauma), on the lung, liver, and kidney organs of rabbits was examined. Administration of LPS to rabbits was more or less injurious to all organs examined as evidenced by an increase in organ weights. Also, a significant increase in lipid peroxidation and a reduction in glutathione levels observed in the organs of LPS-challenged animals are evidence to implicate the involvement of reactive oxygen species as the culprits of the organ injuries. It is documented that LPS induces organ injury, to a great-extent, via oxidative stress-mediated mechanisms.

In conclusion, LPS administration to rabbits appears to be a good animal model in obtaining images of normal and of injured organs. In the next set of experiments (Part II: Investigation of the 2D and 3D High Image Resolution Ultrasonic Technology using Synthetic Aperture and Adaptive Beamformers in control and LPS-challenged rabbits), it is proposed that the LPS-induced organ injury animal model be used to validate the diagnostic superiority of the 3D ultrasound technology over the existing technologies.

Suntres, Z., Stergiopoulos, S. 2002. Part I: Development of an animal model to investigate the 2D and 3D high image resolution ultrasonic technology using synthetic aperture and adaptive beamformers. DRDC Toronto TR 2002-023. DRDC Toronto.



## Sommaire

Lors des opérations militaires, les blessures à la région abdominale sont extrêmement courantes. Les atteintes aux organes comme les poumons, le foie, la rate et les reins peuvent être fatales si elles sont mal diagnostiquées. En outre, les affections telles que les traumatismes gastro-intestinaux et les saignements ou les hémorragies internes passent souvent inaperçues, car il n'existe aucune technique d'imagerie déployable sur le terrain permettant de les diagnostiquer. À l'heure actuelle, les images ultrasonographiques classiques sont bidimensionnelles et l'opérateur doit procéder à une intégration mentale de plusieurs images pour avoir une impression tridimensionnelle des caractéristiques pathologiques ou anatomiques durant une intervention, exercice qui est fastidieux et inefficace et qui exige d'être effectué par un opérateur chevronné, ce qui multiplie les risques de diagnostic et de décision thérapeutique erronés. Par conséquent, il est urgent de mettre au point un système déployable sur le terrain susceptible d'accroître la probabilité de diagnostic sans erreur, afin d'assurer un traitement approprié.

Notre objectif premier est d'élaborer un système d'imagerie diagnostique par ultrasons 3D de deuxième génération, utilisable sur le terrain. Ce système déploiera des réseaux plans grâce à la mise en œuvre d'un traitement adaptatif et synthétique de l'ouverture pour obtenir une haute résolution de l'image. Ce système comprendra les éléments suivants : i) des schémas de formation de faisceau adaptatifs à ouverture synthétique permettant d'obtenir une haute résolution de l'image pour des systèmes diagnostiques ultrasonographiques équivalents à ceux qui déploient des réseaux plans 9 fois plus grands; ii) des techniques de visualisation 3D destinées à assister la production d'images en temps réel durant des interventions présentant un degré minimal d'effractivité.

Afin de valider la supériorité de la technologie ultrasonographique 3D haute résolution par rapport au système bidimensionnel actuel, il est nécessaire d'effectuer des expériences sur des modèles animaux. La majorité des expérimentations de l'ultrasonographie chez les animaux ont été faites chez le lapin. Par conséquent, nous nous proposons d'obtenir des images d'organes normaux et d'organes ayant subi des lésions chez le lapin en utilisant la technologie ultrasonographique actuelle et de comparer ces résultats avec ceux du système d'ultrasonographie tridimensionnelle récemment mis au point.

Comme modèle animal de lésion organique, nous avons étudié l'effet des lipopolysaccharides (un constituant de la paroi cellulaire bactérienne communément utilisé pour provoquer les atteintes pathologiques observées dans les états septiques et les traumatismes) sur les poumons, le foie et les reins du lapin. L'administration de LPS aux animaux a provoqué des lésions plus ou moins graves de tous les organes examinés, comme l'atteste l'augmentation du poids des organes observée. En outre, une augmentation significative de la peroxydation des lipides et une diminution des taux de glutathione dans les organes des animaux ayant reçu des LPS laissent croire que des espèces oxygénées radicalaires interviendraient dans le processus de lésion organique. Il a déjà été démontré que les LPS provoquent des lésions des organes par le biais, dans une grande mesure, de mécanismes liés au stress oxydatif.

En conclusion, l'administration de LPS à des lapins semble être un modèle animal satisfaisant pour obtenir des images d'organes normaux ou ayant subi des lésions. Dans la prochaine série d'expériences (Partie II : Étude des technologies ultrasonographiques 2D et 3D haute résolution faisant appel à des formeurs de faisceaux adaptatifs à ouverture synthétique chez des lapins recevant des LPS et chez des lapins servant de témoins), nous nous proposons de faire appel au modèle animal de lésion organique provoquée par les LPS pour valider la supériorité diagnostique de la technologie ultrasonographique 3D sur les techniques existantes.

Suntres, Z., Stergiopoulos, S. 2002. Part I: Development of an animal model to investigate the 2D and 3D high image resolution ultrasonic technology using synthetic aperture and adaptive beamformers. DRDC Toronto TR 2002-023. DRDC Toronto.

This page intentionally left blank.

## Table of contents

Abstract .....	i
Résumé .....	i
Executive summary .....	iii
Sommaire .....	iv
Table of contents .....	vii
List of figures .....	viii
Introduction .....	1
Materials and methods .....	3
Results .....	4
Discussion and conclusions .....	7
References .....	9

## List of figures

Figure 1. The effect of lipopolysaccharide (LPS) on liver, lung and kidney organs. LPS (20  $\mu\text{g}/\text{kg}$  body weight) was administered to rabbits and the animals were sacrificed 24 h later. Each data point represents the mean  $\pm$ SEM of 3 animals. (\*) denotes a significant difference ( $p < 0.05$ ) compared with the mean value of the saline treated group.....4

Figure 2. The effect of lipopolysaccharide (LPS) on hepatic, pulmonary and renal lipid peroxidation levels. LPS (20  $\mu\text{g}/\text{kg}$  body weight) was administered to rabbits and the animals were sacrificed 24 h later. Each data point represents the mean  $\pm$ SEM of 3 animals. (\*) denotes a significant difference ( $p < 0.05$ ) compared with the mean value of the saline treated group. ....5

Figure 3. The effect of lipopolysaccharide (LPS) on hepatic, pulmonary and renal glutathione. LPS (20  $\mu\text{g}/\text{kg}$  body weight) was administered to rabbits and the animals were sacrificed 24 h later. Each data point represents the mean  $\pm$ SEM of 3 animals. (\*) denotes a significant difference ( $p < 0.05$ ) compared with the mean value of the saline treated group.6

## Introduction

It is well known that during various military operations, injuries to the abdominal region are extremely common (Derby, 1988; Derby, 1987). Damage to organs such as the lung, liver, spleen, and kidney may be fatal if misdiagnosed or treated incorrectly. Furthermore, conditions such as gastrointestinal trauma, and internal bleeding or hemorrhaging are often overlooked since there are no field-deployable imaging techniques available to diagnose such conditions (Derby, 1988; Derby, 1987). Thus, there is a great need to develop a field-deployable imaging system that can increase the probability of correct diagnosis in order to ensure appropriate treatment.

Non-invasive imaging is very useful in assisting medical personnel with rapid diagnosis and therapy of numerous pathological disorders. Thus, several manufacturers of imaging equipment are introducing computerized tomography (CT) and magnetic resonance imaging (MRI) systems that allow for accurate performance of surgical procedures with minimal invasiveness. Unfortunately, these techniques are expensive, non-field deployable, poorly distributed, rarely available, and require a complete surgical suite. Conversely, ultrasound technology not only excels in these domains where CT and MRI fall short, but also allows for surgeons and therapists to observe abnormalities in real time.

Currently, even the most state-of-the-art medical imaging ultrasound systems suffer from poor image resolution as a result of small-sized deployable arrays of sensors, and of the distortion effects caused by the human-body's non-linear propagation characteristics. In particular, some of the limitations (e.g. resolution) of ultrasound imaging are related to fundamental physical aspects of the ultrasound transducer and the interaction of ultrasound with tissues (e.g. aberration effects) (Detmer 1994). In addition, there are limitations related to the display of the ultrasound image in an efficient manner allowing the physician to extract relevant information accurately and reproducibly. It is therefore proposed that a new 3-D ultrasound system is developed that will overcome the following limitations that hinder the success of the current conventional ultrasound imaging system: i) conventional ultrasound images are 2D; hence, the physician must mentally integrate multiple images to develop a 3D impression of the anatomy/pathology during a procedure. This practice is time-consuming, inefficient, and requires a highly skilled operator, all of which can potentially lead to incorrect diagnostic and therapeutic decisions; ii) often the physician requires accurate estimation of tumor and organ volume. The variability in U/S imaging and volume measurements using a conventional 2D technique is high, because the current ultrasound volume measurement techniques assume an idealized elliptical shape and use only simple measures of width in two views (Elliot et al, 1996). 3D images will provide means to obtain accurate and precise organ and tumor volume estimates (Tong et al., 1996); iii) it is difficult to localize the thin 2D-ultrasound image plane in the organ, and difficult to reproduce a particular image location at a later time, making 2D ultrasound a limited imaging modality for monitoring of disease progression/regression and follow-up patient studies; and iv) physicians rely on the use of contrast agents to increase image resolution. However, contrast agents are still relatively new on the market and their long-term side effects have not been well studied. It is therefore uncertain whether they are in fact non-toxic (De Jong et al., 2000; Balen et al., 1994).

Our fundamental purpose, as mentioned previously, is to develop a next-generation field-portable 3-D ultrasound diagnostic imaging system. This system will deploy planar arrays with the implementation of adaptive and synthetic aperture processing for high image resolution. This system will include: i) adaptive and synthetic aperture beamforming schemes to provide high image-resolution for ultrasound diagnostic systems that will be equivalent with those deploying 9 time larger planar arrays; and, ii) 3D visualization imaging techniques to assist real time imaging during minimally invasive operations.

For this work, it is proposed to obtain images of normal and of injured organs in rabbits using the current technology in ultrasonography with and without the use of existing contrast agents and compare these results to the newly developed 3-D ultrasound technology. To validate the superiority of the 3D High Image Resolution Ultrasound technology over the existing 2-D ultrasound technology, it is necessary to perform experiments on animal models. Most of the animal work conducted with ultrasound has been performed on rabbits. Furthermore, pharmaceutical companies have been using rabbits in the testing of their contrast agents, which are used to enhance echogenic signals (Unger et al, 1993; Nishiharu et al., 1998).

## Materials and methods

*Chemicals.* Lipopolysaccharide (LPS, *E.coli* 0111:B<sub>4</sub>) was purchased from the Sigma Chemical Co. (St. Louis, MO). All other chemicals were obtained from the Sigma Chemical Co. or BDH (Toronto, Ont.).

*Animals.* Male New Zealand rabbits (approximate body weight 2.5 - 3 kg) were purchased from Charles River Canada, Inc. (St. Constant, Que.). All animals were housed in stainless-steel cages with free access to pelleted purina laboratory chow and tap water. The animals were kept at room temperature (22 - 24° C) and were exposed to alternate cycles of 12 h light and darkness. Animals used in this study were treated and cared for in accordance with the guidelines contained in the *Guide to the Care and Use of Experimental Animals* as prepared by the *Canadian Council on Animal Care*.

*Treatment of animals.* LPS was dissolved in isotonic saline and prepared shortly before use. Control animals received an equivalent volume of the saline solution.

*Experimental design.* To validate the superiority of the 3D High Image Resolution Ultrasound technology over the existing 2-D ultrasound technology, it is necessary to perform experiments on animal models. Most of the animal work conducted with ultrasound has been performed on rabbits. Furthermore, pharmaceutical companies have been using rabbits in the testing of their contrast agents, which are used to enhance echogenic signals (Unger et al, 1993; Nishiharu et al., 1998). To examine the effect of LPS on lung, liver, and kidney organs, rabbits were injected intravenously with LPS (20 µg/kg body weight) and sacrificed 24 h later. Tissue oxidant activity was assessed by measuring tissue thiobarbituric acid reactants, as a measurement of the degree of lipid peroxidation and GSH levels, a well recognized marker of oxidative stress.

*Tissue preparation.* Liver, lung and kidney organs were removed from animals immediately after decapitation and rinsed with ice-cold saline to remove excess blood. All subsequent steps were carried out at 0 - 4° C. Following rinsing, lungs were quickly weighed and finely minced. Approximately 1 g of tissue sample was homogenized with a Brinkmann Polytron in a sufficient volume of ice-cold 50 mM potassium phosphate buffer, pH 7.4, to produce a 20% homogenate. For the measurement of lipid peroxidation, homogenates were prepared as described previously except the homogenizing medium contained 3 mM ethylenediaminetetraacetic acid (EDTA).

*Determinations of tissue lipid peroxidation and glutathione content* Determination of lipid peroxidation in tissue homogenates was carried out as described by Suntres and Lui, 1991. Reduced glutathione (GSH), more precisely non-protein sulphhydryl, concentrations in tissue homogenates, were determined as described by Suntres and Lui, 1991.

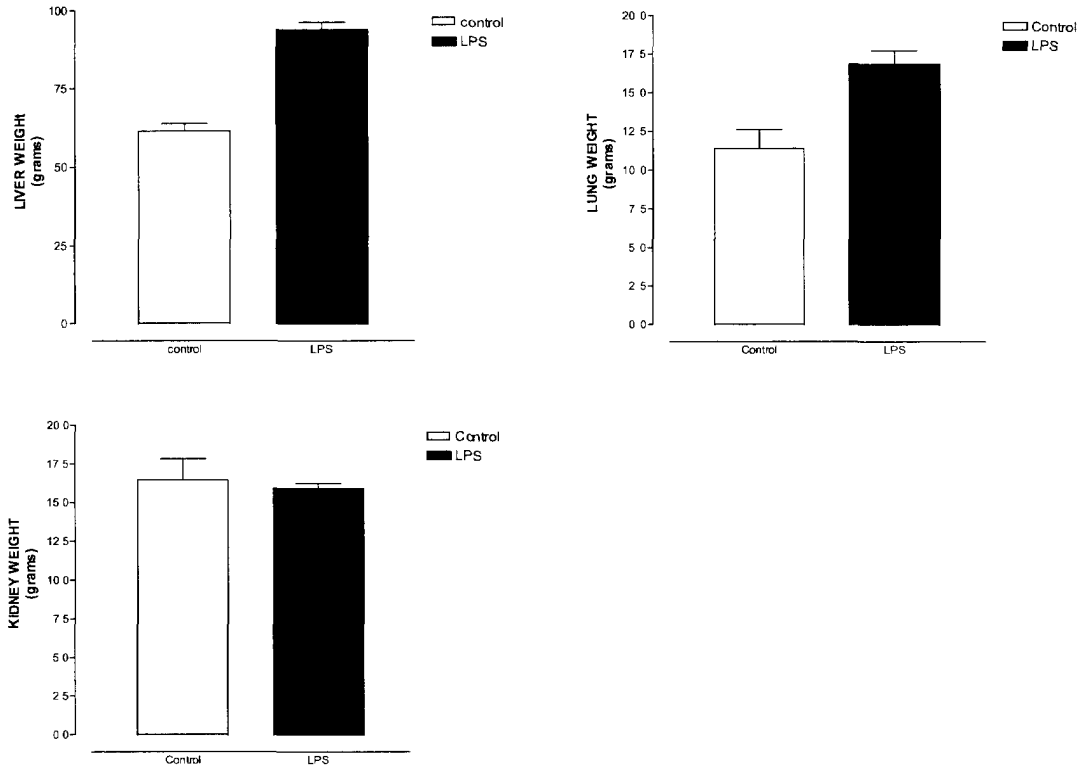
*Statistical Analysis.* Data obtained from control and LPS-challenged were evaluated by one-way analysis of variance (ANOVA). If the F values were significant, the unpaired two-tailed Student's t test was used to compare the treated and the control groups (Gad and Weil, 1982). The level of significance was accepted at  $p < 0.05$



## Results

### Organ weights.

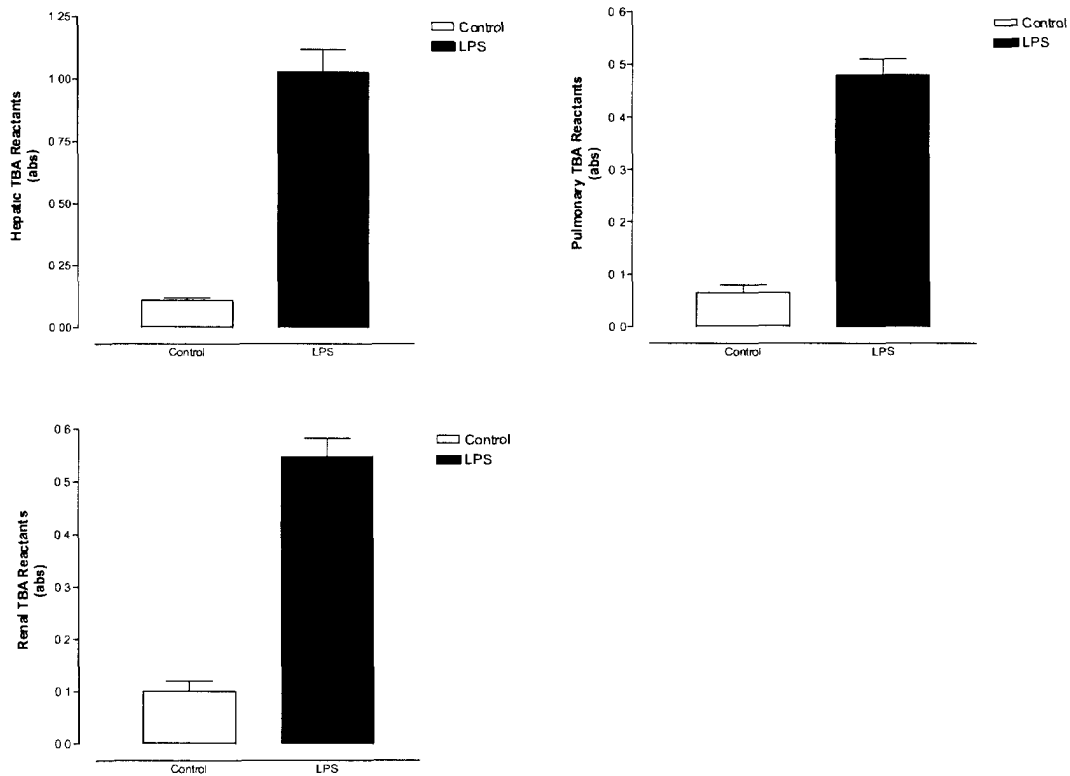
As shown in figure 1, challenge of animals with LPS resulted in significant increases in liver (54% of control,  $p < 0.05$ ) and lung (47% of control,  $p < 0.05$ ) weights with no significant effect on the kidney weight.



**Figure 1.** The effect of lipopolysaccharide (LPS) on liver, lung and kidney organs. LPS (20  $\mu\text{g}/\text{kg}$  body weight) was administered to rabbits and the animals were sacrificed 24 h later. Each data point represents the mean  $\pm$ SEM of 3 animals. (\*) denotes a significant difference ( $p < 0.05$ ) compared with the mean value of the saline treated group

## Lipid peroxidation

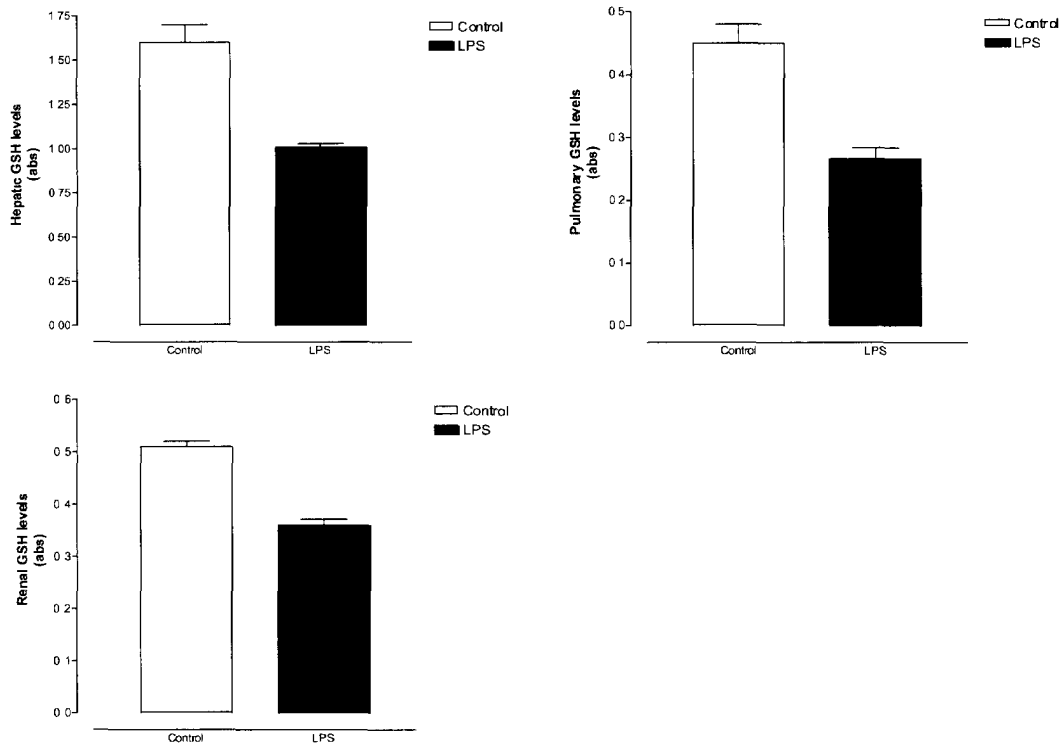
Lipid peroxidation of membrane lipids has been implicated as a possible mechanism of acute oxidative stress-induced lethal injury (22,23). In the present study, animals challenged with LPS produced a significant increase in lipid peroxidation levels in hepatic (9-fold of control,  $p < 0.05$ ), renal (5-fold of control,  $p < 0.05$ ) and pulmonary (7-fold of control,  $p < 0.05$ ) tissue homogenates, as measured by the formation of thiobarbituric acid reactants (figure 2).



**Figure 2.** The effect of lipopolysaccharide (LPS) on hepatic, pulmonary and renal lipid peroxidation levels. LPS (20  $\mu\text{g}/\text{kg}$  body weight) was administered to rabbits and the animals were sacrificed 24 h later. Each data point represents the mean  $\pm$ SEM of 3 animals. (\*) denotes a significant difference ( $p < 0.05$ ) compared with the mean value of the saline treated group.

## Glutathione concentrations

GSH is known to be a sensitive indicator of oxidative stress. In the present study, animals challenged with LPS produced a significant reduction in glutathione levels in hepatic (38% of control,  $p < 0.05$ ), renal (29% of control,  $p < 0.05$ ) and pulmonary (40% of control,  $p < 0.05$ ) tissue homogenates (figure 3).



**Figure 3.** The effect of lipopolysacchande (LPS) on hepatic, pulmonary and renal glutathione. LPS (20 µg/kg body weight) was administered to rabbits and the animals were sacrificed 24 h later. Each data point represents the mean  $\pm$ SEM of 3 animals. (\*) denotes a significant difference ( $p < 0.05$ ) compared with the mean value of the saline treated group.

## Discussion and conclusions

This preliminary work was conducted to develop an animal model of organ injuries so it can be used to obtain images of normal and of injured organs in rabbits using the current technology in ultrasonography with and without the use of existing contrast agents and compare these results to the newly developed 3-D ultrasound technology. The overall objective of this project is to develop an ultrasound system that provides images equivalent to, or better than those derived from current ultrasound modalities that employ contrast agents as enhancers of images. Thus, this technology will reduce or perhaps eliminate the need of using contrast agents in enhancing the images taken by the conventional ultrasound technology.

Organ injury in rabbits was induced following the challenge of rabbits with lipopolysaccharide (LPS). Lipopolysaccharide is a component of cell membranes found in bacteria and has been demonstrated to induce organ injuries (such as liver, kidney, lung, intestines etc) in experimental animals, including the rabbit. In studies examining the disposition of intravenously administered LPS, it has been demonstrated that the liver is the most important and predominant organ of entrapment, followed in importance by the spleen and lung (Skarnes, 1985; Hewett and Roth, 1986). Despite the ability of the liver to detoxify LPS, marked morphological and biochemical alterations occur in hepatic tissues exposed to LPS including zonal hepatic necrosis, formation of fibrin thrombi and hemorrhage (Ben-Shaul et al., 1999; Ben-Shaul et al., 2000; Skarnes, 1985; Hewett and Roth, 1986). Administration of LPS also results in kidney damage characterized by acute tubular necrosis, rupture of the basement membrane, interstitial edema and hemorrhage and glomerular fibrin thrombi (Yokota et al., 1990; Bertani et al., 1989; Archer 1986). Moreover, LPS administration has detrimental effects on the intestinal tract, where the affected portions of the intestine are intensely congested and edematous and frequently blood is found free in the lumen (Archer, 1986).

In this preliminary study, it was demonstrated that intravenous administration of LPS resulted in significant increases in liver and lung weights. Although the mechanism(s) of the LPS-induced increases in organ weights cannot be ascertained from the results of this study, it has been shown that LPS mediates its injurious effects via the generation of reactive oxygen species, known to damage the capillary endothelial cells resulting in edema. An increase in the volume of organs, however, will serve as an excellent model in validating the differences between the current 2D and newly developed 3D ultrasound technology.

The involvement of reactive oxygen species as the culprits of organ injury is supported by evidence presented in this study, where LPS administration resulted in increases in lipid peroxidation and reduction in GSH levels in all organs examined. Oxidative stress, defined as an imbalance between free radical damage and antioxidant protection in the body, leaves behind 'fingerprints' termed biomarkers of oxidative stress status. For example, elevated oxidative stress biomarkers (eg. malonaldehyde measured as thiobarbituric acid reactants) and decreases in the antioxidant cellular status (eg. glutathione) are indicative of cellular injury.

It is concluded, therefore, that the LPS-induced organ injuries in rabbits will serve as a good model in obtaining images of normal and of injured organs, particularly the liver, in rabbits

using the current technology in ultrasonography and the newly developed 3-D ultrasound technology.

In the next set of experiments, it is proposed that the LPS-induced organ injury model be used to validate its diagnostic superiority over the existing technologies.

## References

1. Archer, LT. Pathologic manifestations of septic shock. In: Handbook of Endotoxin: Clinical aspects of endotoxin shock (Proctor, RA, ed), Elsevier, Amsterdam, pp 18-54, 1986.
2. Balen et al., Review: Ultrasound contrast agents. *Clinical Radiology* 49:77-82, 1994.
3. Ben-Shaul V, Lomnitski L, Nyska A, Carbonatto M, Peano S, Zurovsky Y, Bergman M, Eldridge SR, Grossman S. Effect of natural antioxidants and apocynin on LPS-induced endotoxemia in rabbit. *Hum Exp Toxicol.* 19:604-14, 2000
4. Ben-Shaul V, Sofer Y, Bergman M, Zurovsky Y, Grossman S. Lipopolysaccharide-induced oxidative stress in the liver: comparison between rat and rabbit. *Shock* 12:288-93, 1999.
5. Bertani T, Abbate M, Zoja C, Corna D, Perico N, Ghezzi P, Remuzzi G. Tumor necrosis factor induces glomerular damage in the rabbit. *Am J Pathol* 134:419-30, 1989.
6. De Jong et al., Detection procedures of ultrasound contrast agents. *Ultrasonics* 38:87-92, 2000.
7. Derby, AC., Wounds of the abdomen. Part 1: In war. *The Canadian Journal of Surgery* 31:213-218, 1988.
8. Derby, AC., Wounds of the abdomen. Part 2: In peace. *The Canadian Journal of Surgery* 31:307-311, 1988.
9. Detmer P.R, Bashein G, Hodges T, Beach K.W, Filer E.P, Burns D.H, Strandness D.E., 3D Ultrasonic Image Feature Localization Based on Magnetic Scanhead Tracking; in vitro Calibration and Validation. *Ultrasound in Med & Biol* 20: 923-936, 1994.
10. Elliot T.L, Downey D.B, Tong S, McLean C.A, Fenster A, 1996. Accuracy of Prostate Volume Measurements in vitro using three-dimensional Ultrasound. *Academic Radiology* 3: 401-406.
11. Ferrer, FA. et al., Accuracy of renal ultrasound measurements for predicting actual kidney size . *Journal of Urology*, 157: 2278-2281, 1997.
12. Hewett, JA and Roth RA. Hepatic and extrahepatic pathobiology of bacterial lipopolysaccharides. *Pharmacological Reviews*, 45:381-411, 1993.
13. Manthey et al., Ultrasound versus radiography in the detection of soft-tissue foreign bodies. *Annals of emergency medicine* 28:7-9, 1996.
14. Nishiharu et al., Helium Gas Microbubbles. Experimental study on a new ultrasound

- contrast material. *Acta Radiologica* 39:96-99, 1998.
15. Skarnes, RC. In vivo distribution and detoxification of endotoxins. In: *Cellular Biology of Endotoxin* (Berry LJ, ed), Elsevier, Amsterdam, pp. 56-81, 1985.
  16. Suntres, Z.E. and Lui, E.M.K.: Age-related differences in iron-nitritotriacetate hepatotoxicity in the guinea pig: Role of copper metallothionein. *J. Pharmacol. Exp. Ther.* 258:797-806, 1991.
  17. Tong S, Downey D.B, Cardinal H.N, Fenster A, 1996. A three-dimensional Ultrasound Prostate Imaging System. *Ultrasound in Med & Biol* 22: 735-746.
  18. Unger et al., Gas-filled liposomes as echocardiographic contrast agents in rabbits with myocardial infarcts. *Investigative Radiology* 28:1155-1159, 1993.
- Yokota M, Kambayashi J, Tahara H, Kawasaki T, Shiba E, Sakon M, Mori T. Renal insufficiency induced by locally administered endotoxin in rabbits. *Methods Find Exp Clin Pharmacol* 12:487-91, 1990.

## DOCUMENT CONTROL DATA SHEET

1a PERFORMING AGENCY

DRDC Toronto

2 SECURITY CLASSIFICATION

UNCLASSIFIED  
Unlimited distribution -

1b. PUBLISHING AGENCY

DRDC Toronto

3 TITLE

(U) Part I: Development of an Animal Model to Investigate the 2D and 3D High Image Resolution Ultrasonic Technology using Synthetic Aperture and Adaptive Beamformers

4 AUTHORS

Zacharias E Suntres, Stergios Stergiopoulos

5 DATE OF PUBLICATION

April 1 , 2002

6 NO OF PAGES

7 DESCRIPTIVE NOTES

8 SPONSORING/MONITORING/CONTRACTING/TASKING AGENCY

Sponsoring Agency

Monitoring Agency

Contracting Agency

Tasking Agency

9 ORIGINATORS DOCUMENT NO

Technical Report TR 2002-023

10 CONTRACT GRANT AND/OR  
PROJECT NO

11 OTHER DOCUMENT NOS

12 DOCUMENT RELEASABILITY

Unlimited distribution

13 DOCUMENT ANNOUNCEMENT

Unlimited announcement



## 14 ABSTRACT

(U) In recent years, it has been demonstrated that the current ultrasound imaging system may be unreliable due to its poor imaging quality; in several instances, it lacks clarity, specificity, resolution, and sensitivity. These disadvantages have negative consequences when diagnosing patients, since false-positive or false-negative results are sometimes inevitable. It is therefore of great importance to design a new ultrasound imaging system that is able to enhance the images provided by the current technology and subsequently prevent chances for misdiagnosis. An animal model of organ injuries has been established where the current technology in ultrasonography will be tested and compared to the newly developed 3-D ultrasound technology. For this, the effect of lipopolysaccharide (LPS), a bacterial cell wall component, on the lung, liver, and kidney organs of rabbits was examined. Administration of LPS to animals was more or less injurious to all organs examined as evidenced by an increase in organ weights. In addition, a significant increase in lipid peroxidation as well as reduction in glutathione levels in tissue homogenates, confirmed the involvement of oxidative stress as a major mechanism of LPS-induced tissue injury. In conclusion, LPS administration to rabbits appears to produce a good animal model in obtaining images of normal and injured organs that will be used to validate the diagnostic superiority of the 3D ultrasound technology over the existing technologies.

## 15 KEYWORDS, DESCRIPTORS or IDENTIFIERS

(U) ultrasound; organ injuries; lipopolysaccharide; trauma

**Defence R&D Canada**

is the national authority for providing  
Science and Technology (S&T) leadership  
in the advancement and maintenance  
of Canada's defence capabilities.

**R et D pour la défense Canada**

est responsable, au niveau national, pour  
les sciences et la technologie (S et T)  
au service de l'avancement et du maintien des  
capacités de défense du Canada.

# 517 518

CA020775



[www.drdc-rddc.dnd.ca](http://www.drdc-rddc.dnd.ca)